MAR. 2014 Edition, Vol. 1 Issue 1

# STAR DIAGNEWSTICS

*(For Private circulation only.)*

*from* Star Imaging & Path Lab(P) Ltd

Star Imaging & Path Lab (P) Ltd, (SIPL) stands apart by virtue of its being a world class one stop diagnostic Centre of Delhi / NCR since 1978

The SIPL has achieved great rapport with the Medical fraternity because of :

- Reliable, accurate and speedy reporting.
- Highly skilled & qualified professionals.
- State-of-the-art equipment..
- Warm courteous staff.
- Service with a smile.

Star Imaging & Path Lab (P) Ltd. is a pioneer in the comprehensive diagnostic field. In its 35 years of existence, SIPL has grown into a corporate chain of diagnostics centres with 20-state-of-art Branches and 5 Hub with fully equipped diagnostic facilities across Delhi /NCR, serving more than 1000 000 patients annually and more than 10,000 Consulting Doctors all over Delhi /NCR.

At SIPL we pride ourselves for our strong value system that has enabled us to provide quality services to our customers year after year. SIPL's illustrious history establishes its commitment to providing cutting edge solutions. SIPL has always stayed attuned to the latest developments in Radiology & Pathology Department. Insisting on innovation and quality, it is the preferred diagnostic centre for people, hospitals and companies all over Delhi / NCR.

SIPL does not restrict its services to its core activity of diagnostics alone extending support to numerous social causes through their Social Responsibility Program.

## INSIGHT



*"Accurate diagnosis is the spine of Healthcare"*

Dr. R A Gupta
Founder & Chairman

Mr. Pawan Gupta
Managing Director & CEO

***Take the Road Less Traveled.***

Janta X Ray Clinic was incorporated in1978 by Dr. R A Gupta. With the zeal of a missionary, he set about the task of enabling access to world-class diagnostic facilities for the common man.

His credo has been to stay a step-ahead by introducing several modalities in the last 3 decades which were clearly ahead of their times. The list of several firsts to his credit is endless. His stint of 35 years is a saga of bridging the yawning divide between a crying diagnostic need and what is accessible to the populace of West and Outer West Delhi.

His mandate to key stakeholders - Make Accuracy A Habit. The regular infrastructural upgrades and arsenal of world-class medical equipment are his brainchild and widely evident at all the Facilities. At the helm of Janta X Ray Clinic, Star Imaging & Path Lab (P) Ltd. (SIPL) ably guiding the Group's destiny, the word Chairman for Dr. R. A. Gupta would be somewhat inaccurate description.

Chairman Dr. R. A. Gupta is part of the select circle of diagnostic visionaries with an appetite to scale-up Operations which has resulted in SIPL's market Leadership position in West and Outer Delhi.

In his own words, this is what the normally-reticent Chairman has to say - **To be the Biggest is doubtless a coveted aspiration but it is the enthusiasm to be the Best that should never be compromised, under any circumstance.**

*Blaze a trail where no path existed.*

Joining the family business way back in 1997 (then known as Janta X Ray Clinic) became natural progression for Pawan who studied medicine at Mysore's prestigious J.S.S Medical College. Pawan has a sound command over Radiology & Pathology, keeping himself abreast as he does, of latest advancements & developments, thanks to a voracious reading regimen. He is a regular at all CME, RSNA Conferences, both within India & without.

He is an inveterate traveler and genetically endowed with an eye for detail. Like all post-modern CEOs, he is tech-savvy and an incorrigible gizmo freak which enables lot of research work (primarily in Radiology) and which is integral to a fully-informed equipment purchase or upgrade decision. The CEO is the perfect foil to his father, Chairman Gupta and they complement each other and one of the outcomes is that the SIPL cache of Radiology infrastructure is to die for.

One of the earliest initiatives that reflected the MD's ability to bite the bullet was when the-first-of-its-kind Open MRI System from Hitachi was installed in 1999. It went on to become a roaring success almost instantly for it was the first high-end MRI in West & North Delhi. North India's first 32 Slices Per Second CT Scanner came close on its heels. Simultaneously, SIPL achieved the rare distinction of becoming the 1st private Diagnostic brand in North India with the capability to perform Non-Invasive Angiography. And the rest as they say, is history.

RA Gupta
*Founder & Chairman*

NEW at Star

# 3 Tesla + TIM + 70 cms Open Bore MRI

## MAGNETOM Verio

### We Know, We're Excited Too!

Siemens has set a new benchmark in MRI again. As a proven innovator Siemens is bringing 3T field strength, 70 cm Open Bore and Tim™ (Total imaging matrix) together in one powerful system today, MAGNETOM® Verio with the versatility to provide a wide range of clinical applications today and well into the future.

### Why MAGNETOM Verio?

As the newest and most feature-rich 3T system available,MAGNETOM Verio helps you to meet your clinical needs, high standards of patient care, and financial requirements.

### We know 3T

Siemens is a unique 3T innovator. We can prove it.

- More than 10 years of experience in 3T, including the introduction of the world's first 3T whole-body MRI with Tim
- Unique Tim technology that expands the potential of 3T
- 3TCare, the comprehensive solution for Specific Absorption Rate (SAR) enabling maximum efficiency

MAGNETOM Verio brings new benefits.

A unique combination of 3T and 70 cm Open Bore
The shortest 3T system on the market today
Ultra-light magnet with zero helium boil-off
Large field of view, supporting a full range of clinical applications
TrueForm™ magnet design offers enhanced image quality by optimizing the homogeneity
Higher speed and superb image quality powered by the VQ-engine gradient

No Claustrophobia



70 cm Open Bore MRI

Comfortable for Patients Who cannot Lie Straight

Obese Patients can easily be Scanned

TIM (Total Image Matrix)

## Our speciality for other scans in MRI with fast, accurate & guaranteed results.

**Breast MRI**
Staging breast cancer, breast coil well suited for breast biopsy.

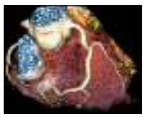

**Cardiac Viability**
All accepted standards and parameters of viability can be evaluated using the various imaging approaches provided by MRI.

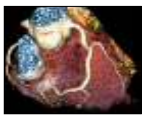

**Cardiac Viability**
All accepted standards and parameters of viability can be evaluated using the various imaging approaches provided by MRI.

**DTI/Tractography**
DTI is the only approach available to track brain white matter fibers non-invasively.

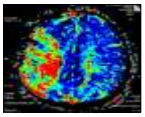

**Neuro Perfusion**
In the timely assessment of ischaemic penumbra and accurate differentiation of recurrent tumors from radiation necrosis.

**Whole Body Diffusion.**
Whole body metastasis screening with TIM technique non contrast comprehensive body metastasis screening

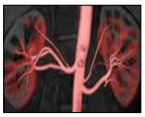

**Non-Contrast Angiography**
Contrast free Thoracic, Abdominal & Peripheral angiography. Accurate artery/vein separation. Very useful for diabetic patients, Renal impaired & contrast allergies.

NEW at Star

# Optima 660 -
## *500 slice CT Scanner*

The Optima CT660 system helps you deliver highly competent, personalized care that helps fulfill your mission and please your patients.
One look at the sleek, compact design tells you this CT system is different. This new-generation, intelligent 500-slice scanner combines the advanced innovations from our Discovery and Light Speed families. You get fast, high quality acquisition at optimized dose for patients young and old, large and small, across a wide spectrum of procedures: cardiac, angiography, brain, chest, abdomen, orthopedic, and more.

Technologists and radiologists benefit from ergonomic features and numerous enhancements in workflow efficiency and diagnostic power. The compact footprint lets the system fit your available space, while a modular design helps you choose capabilities to meet today's budget and expand as you grow.

The Optima CT660 is also environmentally friendly with a design for refurbishment and end-of-life recycling, and with electronics innovations that cut power consumption by 60 percent using the energy saving mode.

- Enhanced table
- User-friendly console
- Synchronized injection
- Personalized touches

## High Image Quality & Ultra Low Radiation

the Low Dose CT Delhi's First High Image Quality at Ultra Low Dose

Complete exams with ease and confidence

## Optima CT 660 Feature

- Innovations in a 40mm detector at 0.35 sec rotation speed.
- Simplified workflow for quick and streamlined operation.
- Advanced applications help clinicians make a fast and confident diagnosis.
- Up to 60% lower Co2 emissions using the energy saving mode.
- Scalable, modular design for ease of service.
- ASIR technology for lower dose exams throughout the body.

## 5 Heart Beat Angiography

Only Center in India to have 5 five dedicated CT Scanners

## Coronary Angiography

FAST & ACCURACY GUARANTEED

Completely Painless-most Safe Method To Get Your Heart Scanned

MARCH 2014
VOL.1 ISSUE 1

NEW at Star

upright and open MRI – that's better!

Introducing

# The G-Scan

G-scan
Esaote Dedicated MRI

*a Total New Definition in MR Imaging*

## Now you can get MRI done while standing, watching TV

Kounteya Sinha | TNN

New Delhi: Do you avoid getting a magnetic resonance imaging (MRI) done because it makes you claustrophobic?

Now, an MRI scan will be as simple as standing in front of a mirror. New-age MRI scanners being put in place can scan people while they simply stand, sit or lie in front of them. And what's best, the new scan machines are noiseless, doing away with that loud knocking sound that can scare anybody out.

Speaking to TOI, eminent radiologist Dr Harsh Mahajan, who has introduced open, standing MRI scanning system, said, "This open, standing MRI system is unique because it can perform scans with the patient lying down, standing or sitting. This enables true weight-bearing examination which was not possible before and was one of the greatest challenges to MR imaging. It is also a boon for claustrophobic patients who are scared of being scanned by the traditional tunnel-shaped scanners."



NO LONGER A CLOSED AFFAIR: The new-age MRI machines can carry out the scan while the person is standing, sitting or lying down in the open

Explaining its benefits, Dr Rajesh Malhotra, professor of orthopedics, All India Institute of Medical Sciences, said that many times, the mechanics of the joint is different when the patient is standing on it or when lying on it. Some people may have stretched ligaments which aren't functioning. This gets exposed when the patient stands up and puts weight on that joint.

"When lying down, the patient hardly puts weight on the lower limb because of which a scan can't pick up some vital problems. When standing, the scan tells us about functional alignments of our joints — how it will behave, progress and whether the condition will get worse. Static MRI tells us the structure of the alignment. But what looks structurally intact can be functionally incompetent," Dr Malhotra told TOI.

According to Dr Mahajan, when we are in a weight-bearing state like in standing position, doctors can see if smaller discs have a problem, is there a reduction in disc height or whether there is a soft tissue bulging out. "When you lie down, everything comes into a neutral position," Dr Mahajan added.

The cost difference isn't much between a normal MRI and the open,standing MRI. While the present day routine MRI costs Rs 6000, the one carried out in standing or lying positions would jointly cost Rs 9,000. "The new machines are also absolutely noiseless," Dr Mahajan added.

Experts say the open MRI design eliminates claustrophobia and accommodates patients of all sizes. It also allows most patients to be able to be scanned without sedation. So now, patients can sit and watch TV during their scan.

## *Open, Standing & Tilting MRI Scan*

**MRI from all angles -** Innovative MRI System, Specially Designed to view Joint like Shoulder, Elbow, Wrist, Ankle, Knee from all angles.

**Weight Bearing Technology -** One of its kind Technology where MRI can be done in supine (Lateral) or Upright standing Position.

# Save Water
# Go Green

Saves water by using DRY CHEMISTRY analyzer in Lab

NEW at Star

# "Walk on the path of right diagnosis because accurate diagnosis is the spine of Healthcare"

**Star Imaging & Path Lab(P) Ltd**

We, at Star understand that proper diagnosis is critical for patient care. Taking this belief in heart we have partnered with Johnson & Johnson (Ortho Clinical Diagnostics) to ensure world class timely results through efficiently consolidated critical testing.

*Because we are obsessed with quality since 1978.*

## Ortho Clinical Diagnostics

a Johnson & Johnson company


- Standardized reagents and results across all platforms
- Patented enabling technologies that maximize resources and minimize interventions
- Accessible menu on-board at all times
- Over 120 available assays and 10 user-defined chemistry channels
- Flexible configurations, process assessment and automation solutions
- Unrivalled service and support
- Our commitment to constant menu evaluation and launching new assays for the future

ONLY at Star

# MR - Iron Study

## First Time in India, we have launched

### a New Software in MRI at Tilak Nagar for treatment management of the Thalassemia

*MRI T2* for assessment of iron overload in Heart and Liver in Thalassemic patients. Iron overloads in Heart and Liver leads to Heart failure & Cirrhosis of Liver.*


- *1.5T Wide Bore MRI- with Tim Technology 70 cms Wide Bore - Now, even Obese patients can be easily scanned.*
- *No Claustrophobia- Patients Head out for most of the applications, including L-Spine Comfortable Scans- Even for the patients with respiratory issues. Pain & Mobility issues & Kyphosis Tim-Total Imaging*
- *Matrix - For Accurate, Speed and Flexible Scans. For Fast Whole Body MRI Scans.*
- *Syngo Blade - Special Software to eliminate motion related artifacts.*
- *Minimises Sedation Rate - Even Pediatrics Patients can be easily Scanned*

NATIONAL THALASSEMIA WELFARE SOCIETY

**National Thalassemia Welfare Society (Regd.)**

ORGANISATION FOR AWARENESS OF THALASSEMIA AND TO HELP THALASSEMICS

**Dr. J.S. Arora**
*General Secretary*
**Thalassemialogist**
**MSC in Haemoglobinopathy**
**University College London, UK**

We are delighted to know that Star Imaging and Path Lab (P) Ltd. has taken lead to introduce new technology MRIT2* for assessment of liver iron concentration and and heart respectively in transfusion dependent disorders like Thalassemia, Sickle Cell Anemia, Myelodysplastic Syndrome etc.

Results are reliable, reproducible and correlate well with the clinical condition of the patient. This technology is widely used in the west for monitoring of iron overload in multiple transfused Thalassemia patients. This will help us a lot in keeping a check on iron overload in thalassemics.

We congratulate M/s Star Imaging and Path Lab (P) Ltd. for making this new iron assessment tool for our patients at affordable cost. We wish them a grand success in their this new venture.

NEW in New Delhi

# Whole Body MRI Screening

exclusively at

**Star Imaging & Path Lab(P) Ltd**

Now, in just 45 minutes, get a complete screening from head-to-toe on India's fastest and most patient friendly MRI with wide bore for maximum patient comfort.

Whole Body MRI evaluates all the organs in the body including head, neck, chest, abdomen, pelvis, musculoskeleton, and whole spine.

## Whole Body MRI Screening

- Is completely harmless with no exposure to radiation. Fully non-invasive with no injection of contrast.
- Has no side effects.
- Requires no prior preparations.
- Complements other diagnostic investigations such as Sonography and Colour Doppler for a more thorough evaluation of any disease



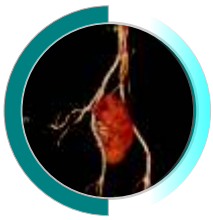



## Open to new experiences?

Experience the new Open Bore 3T MRI

- **Comfort** — The more open design accommodates different size patients - and helps reduce anxiety and claustrophobia.
- **Speed** — Exclusive Tim (Total imaging matrix) technology helps to make exams faster.
- **Confidence** — The powerful magnet provides extraordinary images so your doctor can have greater diagnostic confidence.

**Now available at Star Imaging & Path Lab (P) Ltd.**

# JOIN US IN THE FIGHT

1 in 8 women will be diagnosed with breast cancer in their lifetime


## UNDERSTANDING CANCER

Our body is made up of cells. All cancers begin in cells, which are the fundamental unit of life. To understand cancer, it's useful to know what happens when normal cells become cancer cells.

The body is composed of a variety of cells. These different types of cells grow in a well-controlled, steady manner to produce more cells that keep the body growing and functioning normally. As cells age or are damaged, they die and are replaced. But if this normal pattern is interrupted, then there will be an abnormal reaction from the cells. This reaction will come from one area or organ of the body where the cells continue to multiply and live beyond their life span. These cells are the cancerous cells.

Cancer is a medical condition where there is:
Abnormal and uncontrolled multiplication of body cells.
One organ or part of the body where the cancer begins.
A group of mutant cells that migrate and invade other parts of the body through blood and lymph.
Manifestation of the disease in the form of a tumour, which is a group of mutant cells that form a tissue.
Risk to all, regardless of gender or age.
A cause that is multi-factorial and where the disease process differs at different sites.
According to a World Health Organization report, premature deaths by non-communicable diseases is one of the highest in India. Of all the other non-communicable diseases like cardiovascular ailments, chronic respiratory problems and diabetes, cancer is a major public health concern.
The cancer burden in developing countries is reaching pandemic proportions. Cancer is one of the leading causes of death in India, with about 2.5 million cancer patients, 1 million new cases added every year and with a chance of the disease rising five-fold by 2025. Indian Council of Medical Research (ICMR) has urged the Government of India to make cancer a notifiable disease. There is a high probability of treating cancers if detected early -- in Stage I or Stage II. 70-80% of cancer patients are diagnosed late when treatment is less efficient and 60% of them do not have access to quality cancer treatment. Out of 300+ cancer centres in India, 40% are not adequately equipped with advanced cancer care equipment. This study further suggests India will need at least 600 additional cancer care centres to meet the requirements by 2020. Nearly 5 lakh people die of cancer in India. As per WHO Report 2005, this number is only expected to rise to 7 lakh by 2015.

Globocan 2008 report shows that in India, cancers of lung and mouth in men and cervix and breast in women are the biggest killers.
The causes of such high incidence rates of cancer may be both internal (genetic, mutations, hormonal, poor immune conditions) and external or environmental factors (food habits, industrialization, over growth of population, lifestyle-related). Ignorance among public, delayed diagnosis and lack of adequate medical facilities has given cancer the dubious distinction of being a 'killer disease'. However, fact remains that if cancer is detected in its early stages, it can be treated and individual can lead a healthy life. To fight cancer, governments in many countries maintain population-based cancer registries.

### Cancer registry in India

Cancer registration is a mechanism to collect and classify information on all cancer cases in order to produce statistics on the occurrence of cancer. It also helps in assessing and controlling the impact of cancer on the community.

In many developed countries and in some states of USA, notification of cancer cases is compulsory for every hospital. This facilitates collection of data for population-based cancer registries.

In areas where notification is compulsory, hospitals retrieve information from the patient records on a specified proforma and send it to the registry. (This is called the passive method)

A report on cancer registration in India says, "In areas where trained staff for abstracting the records is not available with the individual hospitals or notification is not mandatory, the workers from registry scan through the patient records in different hospitals, clarify incomplete or contradictory information, and abstract data." This method is known as active method.

National Centre for Disease Informatics and Research, a dedicated government institute which collects cancer data, operates through 219 centres across India comprising 28 population-based cancer registries which have 250 major institutions contributing to data base.

*Cancer is NOT Dangerous if detected on time.*

NEW in New Delhi

*introduces*

# *Whole body Cancer Screening*

*Cancer is NOT Dangerous if detected on time.*

***Be pro-active in your health! Get screened...***

**get Screened.**

*Preventive Screening*

**get in gear**

COLORECTAL CANCER

BREAST CANCER

PROSTATE CANCER

Take Control of your Health

CERVICAL CANCER

SKIN CANCER

"Can be **stopped** before it **starts**"

"**One of the few preventable cancers**"

"**screening saves lives**"

**There's no doubt.**

## The seven early signs of cancer

- *Change in bowel or bladder habits*
- *A sore that does not heal*
- *Unusual bleeding or discharge*
- *Thickening or lump in the breast, testicles, or elsewhere*
- *Indigestion or difficulty swallowing*
- *Obvious change in the size, color, shape, or thickness of a wart, mole, or mouth sore*
- *Nagging cough or hoarseness*

## The following symptoms may also signal the presence of some types of cancer

- Persistent headaches
- Unexplained loss of weight or loss of appetite
- Chronic pain in bones or any other areas of the body
- Persistent fatigue, nausea, or vomiting
- Persistent low-grade fever, either constant or intermittent
- Repeated infection

## *Star Cancer Screening Profile*

| TEST | DESCRIPTION | GENDER |
|---|---|---|
| AFP | For Liver, Germ cells cancer of ovaries, Testes | ♂ ♀ |
| CA 19.9 | Pancreatic, Colorectal, Bile duct | ♂ ♀ |
| CEA | Colorectal, Breast, Thyroid, Liver, Pancreatic, Cervix and Bladder | ♂ ♀ |
| CA 15.3 | Breast cancer, Lungs, Ovaries | ♀ |
| CA 125 | Ovarian | ♀ |
| PSA (Total) | Prostatic Cancer | ♂ |
| Liquid PAP Smear | Cervical Cancer | ♀ |

Dr. Sameer Sood
Radiologist

# Article-01 Case History

## Pulmonary Alveolar Microlithiasis – Case report.

A 45 year old male was referred to Dept of CT scan, Star imaging and Path lab for HRCT chest , with the chief complaint of dyspnoea for the last 2 years.

### HRCT findings

High-resolution computed tomography of the lungs showing bilateral calcifications with increased attenuation involving alveoli, intra- and interlobular septa, fissures and pleura, with predominant involvement of bilateral middle and lower lobes. Signs of fibrosis are visible. Hounsfield unit measurements were very high, representing areas with calcifications. Associated intraparenchymal cysts are also seen in the left upper lobe.

### Discussion

Pulmonary alveolar microlithiasis (PAM) is a rare idiopathic condition characterised by widespread intra alveolar deposition of spherical calcium phosphate microliths. The exact aetiology and pathogenesis is not well known.

A slight female predilection may be present . Often discovered incidentally on a chest radiograph. The radiographic features are frequently out of proportion to clinical symptoms.

On radiographs, pulmonary alveolar microlithiasis is characterized by diffuse fine calcific micronodules that involve both lungs in a pattern that is classically described as sandstorm-like . Increased calcific densities are often more pronounced in the lower lung zones, a fact that has been attributed to the larger surface area and greater thickness of the lower part of the lungs . Obscuration of the mediastinal and diaphragmatic reflections by extensive microliths is common. A vertical linear radiolucency between the ribs and lung parenchyma is also a common finding in the presence of pulmonary alveolar microlithiasis and is likely secondary to the subpleural cystic changes that are often seen at cross-sectional imaging and pathologic evaluation. Small apical bullae are another typical feature, and an associated pneumothorax may be seen .

High-resolution CT with thin-section acquisitions and high-spatial-frequency reconstruction algorithms is preferred for the evaluation of pulmonary alveolar microlithiasis because it allows detection of minimal structural changes of the lung parenchyma that are not optimally evaluated with radiography or with other CT techniques . The characteristic finding of extensive innumerable microliths involving both lungs is noted with a predisposition for the posterior segments of the lower lobes and anterior segments of the upper lobes . Additionally, the medial aspect of the lung appears to be more heavily involved than the lateral aspect.. Confluent areas of calcifications may be identified, often in the upper lobes . These findings correlate with the hard calcified micronodular appearance of the lung parenchyma seen at gross pathologic evaluation and the classic concentric lamellar calcified microliths that are seen in the interstitium at hematoxylin-eosin staining.

High concentrations of microliths within the periphery of the secondary pulmonary lobule are likely responsible for the micronodulation and thickening of the interlobular septa that are often seen at high-resolution CT . Microliths can also be seen along the bronchovascular and subpleural interstitium, resulting in a thickened, micronodular appearance of these structures . Calcifications of the pleura also have been reported .Microliths with a diameter of less than 1 mm produce a ground-glass appearance and, with appropriate windowing, can often be discerned as discrete calcifications . Numerous thin-walled small subpleural cysts, which likely account for the dark pleural line seen on radiographs, are another common feature of pulmonary alveolar microlithiasis.

Extensive calcifications resulting in interlobular septal thickening and ground-glass opacification may create an appearance that resembles the “crazy paving” pattern seen in pulmonary alveolar proteinosis . However, discrete calcifications visualized with appropriate window settings may help distinguish pulmonary alveolar microlithiasis from pulmonary alveolar proteinosis. Additional differential considerations include sarcoidosis, pneumoconiosis, pulmonary hemosiderosis, amyloidosis, miliary tuberculosis, and metastatic pulmonary calcifications associated with chronic renal failure .Most patients remain symptom-free for many years despite extensive radiological changes.

# Article-02

## Agenesis of Dorsal Pancreas

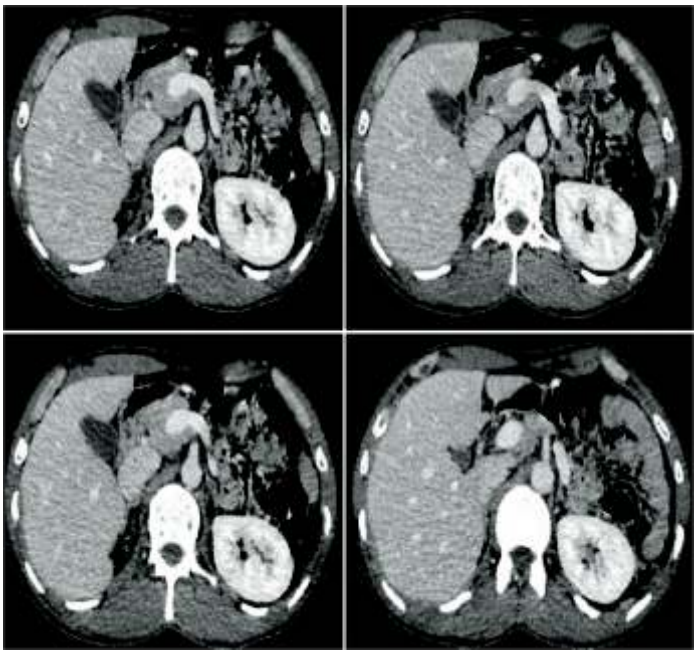

Agenesis of dorsal bud of the pancreas is an extremely rare congenital anomaly which results in absence of neck, body and tail of the adult pancreas. The severity of the disease depends on the amount of functional pancreatic tissue present. It may be associated with number of clinical features like diabetes mellitus, abdominal pain and chronic pancreatitis.

DISCUSSION:
Agenesis of the dorsal pancreas is a rare anomaly. Patients will commonly present with acute onset abdominal pain and a medical history of diabetes.
A 33 years old lady presented with acute upper abdominal pan. Computed tomography showed absence of neck, body and tail of pancreas anterior to splenic vein and portal confluence; however head and uncinate process were normally present. Patient was thus diagnosed as agenesis of dorsal bud of pancreas. The patient also had a malpositioned and malrotated left kidney.
Unlike many other cases of agenesis of the dorsal pancreas, this patient had no history of diabetes mellitus or prior pancreatitis.

Agenesis of the dorsal pancreas results from an embryological failure of the dorsal pancreatic bud to form the body and tail of the pancreas.
Partial dorsal pancreatic agenesis may be appreciated as a short, rounded pancreatic head adjacent to the duodenum with absence of the pancreatic neck, body, and tail. With with complete agenesis of the dorsal pancreas, the neck, body, and tail of the pancreas, the duct of Santorini, and the minor duodenal papilla are all absent. With partial agenesis of the dorsal pancreas, the size of the body of the pancreas varies, there is a remnant of the duct of Santorini, and the minor duodenal papilla is present.
While complete agenesis of the dorsal pancreas is extremely rare, partial agenesis of the dorsal pancreas is thought to be commoner than ventral pancreatic agenesis.

The cause for acute onset abdominal pain is as of yet undetermined. It has been hypothesized that the variant pancreatic duct system may cause insufficient drainage, causing acute, intermittent or chronic pancreatitis.[1] However, no findings of pancreatitis were demonstrated in this case.

Associations
- Hyperglycemia: may be present in a significant proportion of cases (i.e. upto 50%)
- Solid-pseudopapillary tumour of the pancreas:
- Polysplenia
- Pancreatitis

The principle differential diagnosis is pancreas divisum.

CONCLUSION:
Advances in multidetector CT, including increased resolution coupled with the ability to view studies in the sagittal and coronal planes, allows diagnosis of congenital anomalies of the pancreas non-invasively.

# Infrastructure at par with global standards

Magnetom Verio 3T MRI
Wide Bore With TIM Technology

500 Slice
CT Scanner

Architect
*Ci 8200*

Architect
*Ci 4100*

VITROS System Chemistry
*4600*

VITROS System Chemistry
*3600*

## *Why Star ?*

### *Key Differential*

- Biggest & Best portfolio of **5 MRI units** which include 3 Tesla, 1.5 Tesla & G-Scan.
- Best collection of **5 CT Scanners** which include GEs Optima 660 ( Lowest Radiation dose ).
- World Class & **fully automated Pathology** main lab with backup lab.
- Architect ci4100 & ci8200 **(Abbott)** & Vitros 3600 & Vitros 4600 **(Johnson & Johnson).**
- Biggest portfolio of latest & most modern **4D Ultrasound units** from GE & Samsung.
- Multiple **Dexa BMDs** with whole body scanning facility.
- Dedicated VIVID 7 for doing **Dynamic Echocardiography** by DM Cardiologists.
- Paediatric Coronary Imaging & **5 Beat Cardiac Angiography** using Dynamic CT AngioTools.
- Best Faculty - Star has **30 Full time MD Radiologists & Pathologists** for Best Diagnosis.
- **Biggest Branch Network** in Delhi & NCR ( Hub's in Tilak Nagar, VikasPuri, JanakPuri, Pusa Road & Green Park ).
- **Widest Tests Menu** & Most advanced test parameters- ( Vit D , Vit B12 , Liquid Based cytology & VP III ).
- Uncompromised quality of reporting & test diagnosis - all under one roof - at **Tilak Nagar Mega Hub.**
- **24x7 Emergency services** for both MRI & CT with prompt reporting facility.

# *From the Editor's Desk*

*Star Imaging & Path Lab (SIPL) mission is to provide complete diagnostic facilities & solutions with an aim & objective of bringing world class & most modern diagnostic facilities to the reach of the common man and, provide them with accurate diagnosis in the fields of Radiology, Pathology, Cardiology & Neurology. SIPL vision statement describes what the organization hopes to achieve five years down the line. By 2020, SIPL will demonstrate significant impact in diagnostic field with its inherent strengths and if required, in collaboration with other partners as well.*

Monika Gupta
Chief Editor
Managing Director & Head of Quality Assurance

Sameer Bhati
Asst. Editor
Sr. Mgr - Marketing & Bus. Development

Single Point of Contact @ **Star**

Sudhanshu Gupta
Executive Director & Chief Operating Officer

*For Feedback, Suggestions, Business tie-ups & Franchise enquiries, please call up 9891702454 or mail me at: achiever_sgupta@yahoo.co.in*

NABH

M-0054 NABL ACCREDITED

Quality austria

visit us at: starimaging.in

# Widest Branch Network Spanning West Delhi, Outer Delhi, Central & South Delhi leading upto Gurgaon with Full Equipped Centres.

**HUB 1**
C1/7, Opp. Mata Channan Devi Hospital, Janak Puri, N. D.-58
Ph.: 4057 4111-118

**HUB 2**
A-6, Vikas Puri,
New Delhi-110058
Ph.: 45655200 (100 Lines)

**HUB 3**
17, Pusa Road, Opp. Pillar No.94,
New Delhi-110005
Ph.: 011-49244000, (100 Lines)

**HUB 4**
A-23, Green Park, Main Aurbindo Road, New Delhi-110016
Ph.: 26866134, 9990019170

**Rural HUB**
Plot -1-A, Naya Bazar, Near 817 Bus Stand, Najafgarh, N. D.-43
Ph.: 64539800, 25325368

## Central Zone

### Janak Puri
C-3/86, Ground floor, Janak Puri
(Near Orchid Hospital)
Ph.: 46109454, 9990019114, 9990019119

### Vikas Puri
DG-3/277, Ground Floor, Vikas Puri,
New Delhi-18 Ph.: 47321491, 9990019197

### Uttam Nagar / Mohan Garden
C-1/29, Opp. Metro Pillar No. 741,
Mohan Garden,Najafgarh Road, Uttam Nagar,
New Delhi Ph.: 25356832, 9990019256

## South Central Zone

### Hari Nagar
WZ-409/B1, Plot No. 5, Janak Park,
Opp. DDU Hospital, New Delhi-110064
Ph.: 64589800, 25491293, 9990019183

### Ramesh Nagar/Raja Garden
J-31, Najafgarh Road, Ramesh Nagar,
(Opp. Metro Pillar No. 363), Ratan Shafakhana,
New Delhi Ph.: 64739800, 25453135

### Paschim Vihar/Punjabi Bagh
Block B-3, Paschim Vihar, New Delhi-63
Ph.: 65452532, 45751757

## Outer West Zone

### Bijwasan Palam Vihar
74, Main Road, Near Palam Vihar Crossing
Bijwasan, New Delhi-110061
Ph.: 64509800, 28061957

### Sagarpur Chowk
639, Street No. 11, Vashisth Park,
Main Pankhs Road,Near Gurudwara,
Ph.: 28524802, 9990019232

### Shastri Nagar
E2-255-B, Below Metro Station,
Shastri Nagar, (Opp. Metro Pillar No. 164)
Ph.: 23652210 / 15

### Dwarka
E-555, Ramphal Chowk, Sec-7, Dwarka,
New Delhi-110075
Ph.: 45108887, 9990872384
Flat No. 1A, Pocket 2, Sector 6, Dwarka
Ph.: 42415171

### Palam
RZ-86, Raj Nagar, Palam Colony,
(Opp. Pillar No.35) New Delhi-110045
Ph.: 64619800, 25364425

## Patient Service Center (PSC)

D-740, Main Rohtak Road,
Nangloi, N.D.-41
Ph.: 65390139, 25949314

D1A/140, Janak Puri,
New Delhi-110058
Ph.: 47059487, 9990872386

A-1/169 A, (Shishu Sadan)
Janak Puri,New Delhi-110058
Ph.: 4106 0610 - 617

C5A/305 A, (Near Kadimi Market)
Janak Puri,New Delhi-58
Ph.: 011-45143171, 9990019101-102

## Any Time Assistance

| | | | |
|---|---|---|---|
| Sameer Bhati | 99900 19101/102 | Dr. Namerta Panade | 99900 19220 |
| Arun Upmanyu | 99900 19103/104 | Dr. Arvind Sharma | 9910339195 |
| Vikram Malhotra | 99900 19105/106 | Meenakshi Gupta | 99900 19140 |

**Star Imaging & Path Lab(P) Ltd**
Established in 1978 as *Janta X-Ray Clinic*®

Our Mega Hub in Tilak Nagar Comprises of:
4B/3, 4B/4, 4B/5 & 4A/16, Tilak Nagar, New Delhi-110018
Ph.: 45106300, 45602200, 45655200 (100 Lines)
www.starimaging.in